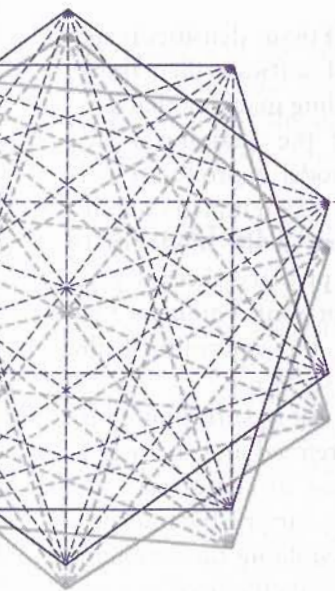

## CHAPTER 20

# Three-Dimensional Computer Modeling

WILLIAM J. BINDER  
ALAN KAYE

This chapter discusses the principles, method, and benefits of combining three-dimensional (3D) computed tomographic (CT) imaging with 3D computer-aided design–computer-aided manufacturing (CAD-CAM) technology to assist in the fabrication of custom-designed implants for the treatment of complex contour deformities. The process generates a greater level of precision in implant design, forming the implant's posterior surface to fit the underlying bone base exactly and thus preventing slippage and providing for long-term stability. The procedure primarily is performed as an outpatient procedure, providing a reliable, accurate, and cost-effective method of contour restoration with little morbidity and reduced time in surgery.

Accurate qualitative and quantitative reconstructive of facial contour defects and the *reliable production of* implants or grafts for correction of surface incongruities have continued to pose a challenge for the aesthetic or reconstructive surgeon. The type of restorative procedure chosen often depends on the training and experience of the treating surgeon: the oral maxillofacial or craniofacial surgeon will favor osteotomies and the use of bone grafts, whereas those surgeons trained in other subspecialties of reconstructive surgery might use other procedures. Within the past year or so, some of the basic concepts of orthognathic surgery have been challenged; that is, the aesthetic outcome has become as important as occlusal or functional success.<sup>8,18,19</sup> As this trend continues, we can expect to see different treatment ap-

proaches more frequently considered in solving age-old problems.

Because of the complexity of craniofacial anatomy, overlapping shadows, and magnification artifact, precise assessment of the bones of the head and neck using standard radiographs has always been difficult. Computed tomography (CT) scanners have made standard x-ray films almost obsolete in the diagnosis and treatment planning of craniofacial eccentricities, maxillofacial trauma, and most head and neck disorders. With 3D images obtained by reformatting computerized data from CT scans, a greater level of precision can be reached in the treatment planning and presentation of complex craniofacial procedures.<sup>9,12,18,23,27</sup> The use of higher resolution and faster helical CT scanners, more advanced 3D *imaging and modeling* techniques, and stereolithography have provided an advanced level in treatment planning and produced more accurate prosthetic devices that have set a new standard of care.<sup>21,24</sup>

Connecting the new imaging technologies to 3D CAD-CAM software produces a life-size model of a specific anatomical area (computer modeling), which allows the surgeon to physically analyze and examine nuances of contour while visualizing spatial relationships in endless perspectives. The posterior surface of the implant produced by the 3D modeling process fits the underlying bone base precisely. This interlocking implant-bone interface guides exact placement of the implant, contributing to a greater degree of stability. Surface

molding techniques are also used to estimate volumetric parameters and reliably predict the amount of augmentation required for the most desirable change in external contour. The model is used as the foundation on which to design precise onlay implants, which improve stability and allow greater accuracy in placement and form to aesthetically enhance and restore facial contour.

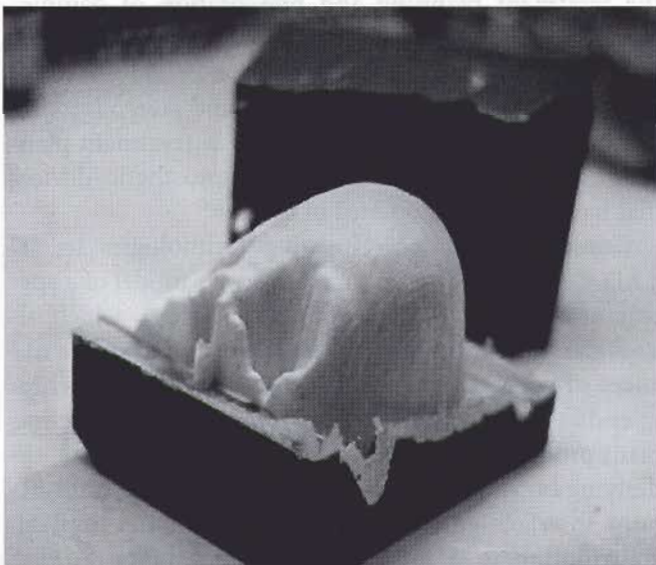
In our experience the use of 3D modeling, although offering significant advantages, is not necessary in most routine cases of aesthetic facial contouring. Current computer-designed "off-the-shelf" implants satisfy the needs of most routine aesthetic enhancement and facial rejuvenation procedures.<sup>2,3,7,23</sup>

## METHOD

Using a set protocol, a CT scanner makes an image of the area of anatomical interest. It is important that the surgeon provide the CT technician or radiologist with the specific scanning instructions needed to obtain the digital information needed to ensure successful 3D conversion. Technical information, radiological protocols, and a list of CT scanners compatible with this process are provided by the manufacturer.\*

This protocol delivers minimum radiation exposure by using minimum slice thickness to scan the area of interest and contextual slices of greater thickness with lower dose techniques to scan the surrounding areas.<sup>27</sup> The CT data is reformatted into a 3D image either by the CT scanner workstation or by a commercial imaging and modeling facility. Additional processing of the data, such

\*Implantech, Ventura, California.



as mirror imaging or measuring of tissue densities is also available. Conversion CAD-CAM software then transfers the reformatted data to a milling machine that produces a life-sized 3D model of the anatomical area scanned (Fig. 20-1). Once the model is produced, it is used as the foundation on which wax templates are designed to fill the defects anywhere in the model or to build up malformations of the primary skeletal part. When soft tissue deficiencies are present, a moulage may provide additional information for determining the contour of the implant's external surface.

The edges of the implant adjacent to surrounding irregularities of the defect can be refined and the overall thickness of the implant adjusted to compensate for overlying soft tissue deficiencies by carving the thickness and shape of the wax template. Molding the wax template directly on the model highlights the need to compensate for these unusual deviations in skeletal anatomy. Manipulation of the wax template before the fabrication of the implant also provides an invaluable opportunity to preoperatively anticipate changes necessary to achieve the optimal external contour. It is important, however, to remember that the posterior surface of the template approximating the bone interface always remains constant. This technique lends itself to the correction of both major bony defects and smaller, subtle bone or soft tissue deficiencies that in the past might have been considered too elusive for correction. Once the template is completed, a stable heat-vulcanized silicone elastomer implant that is an exact replica of the template is produced commercially.

The key to the long-term success and stability of larger implants is the exact fit between the implant's posterio-

**FIGURE 20-1** The 3D digital image originating from CT data is transferred via conversion CAD-CAM software to a milling machine to create the mold into which resin is poured to produce the anatomical model. (From Binder W, Kaye A: 3-D computer modelling: used to create custom-designed implants for treating aesthetic and acquired facial contour deformities, *Facial Plast Surg Clin North Am* 2(3):357-371, 1994.)

or surface and the underlying skeletal framework. In cases in which the amount of external contour correction is in doubt, the implant is fabricated slightly larger than the estimated ideal and is modified during surgery.

## CLINICAL EXPERIENCE

To date we have treated 47 patients with custom-designed silicone elastomer implants generated from the 3D imaging and modeling process. Custom implant fabrication was indispensable in these cases in which previous attempts with older techniques of grafts, implants, or other reconstructive modalities failed to achieve satisfactory results. In all cases the patient's preoperative expectations were met and, in the majority of cases, were exceeded. The procedure proved to be reliable and predictable with near 100% correction for specific defects limited to the bony skeleton. Conditions in which associated soft tissue or bone loss also required augmentation, the process was subject to degrees of error based on the surgeon's estimate of the amount of soft tissue augmentation required or the amount of soft tissue loss contributing to the topographical defect. The greater than 95% success rate of these procedures was determined ultimately by surgeon and patient satisfaction and by whether the results met the surgeon's original expectations.

The posttraumatic deficiencies were made up of displaced zygomatic complex fractures, bony defects of the inferior and superior orbital rim, maxilla, premaxilla, peripiriform area, and midforehead. Cases of congenital facial deformities involving the midface and mandible represented complex residual deformities that remained after orthognathic surgery. In some patients who previously had had unsuccessful procedures the custom implants were indispensable for the final resolution of their contour deficiencies. In patients in whom second stage procedures were required, the permanent model facilitated the design and fabrication of new implants. In patients with unilateral defects the external contour of each implant was designed to match the contralateral normal bone prominences, thereby restoring symmetry. In many patients this proved to be an accurate and simple means to reconstruct difficult problems, whereas in others it was the only treatment that could provide a reasonable degree of success.

In all but three cases the surgical procedures were performed on an outpatient basis. The anatomical models were utilized for preoperative planning, determining landmarks and measurements and for correct implant design and placement. An attempt was made to use standard surgical approaches and to place incisions in

healthy tissue at some distance from the implant site and away from areas of excessive scarring. In each case of skeletal deficiency we found the fit of the inferior surface of the implant to the underlying bone to be so perfect that it actually provided its own guide for placement. The added stability obtained by the interlocking process of the implant-bone interface in most cases made internal or external fixation almost totally unnecessary.

## CASE REPORTS

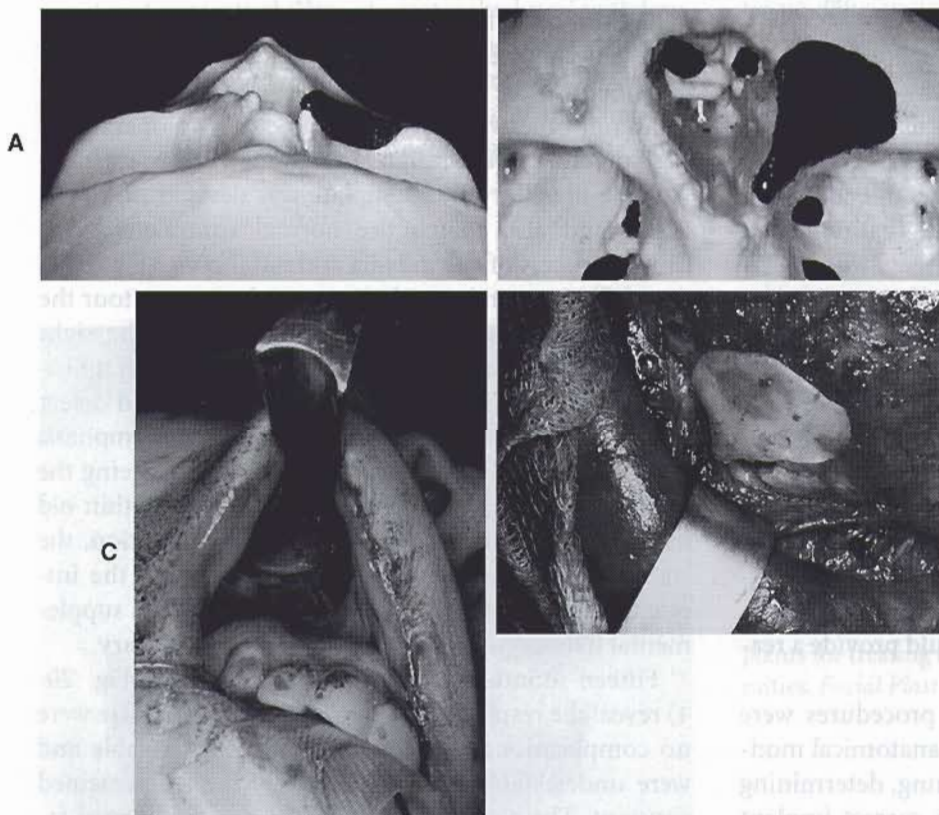
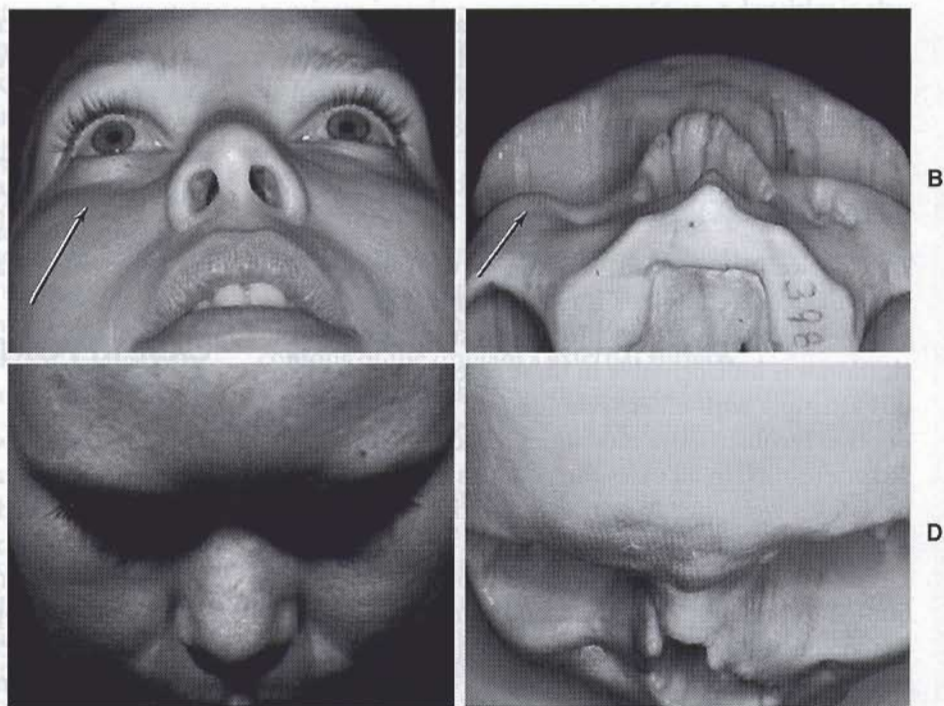
### Case 1

This 34-year-old woman was involved in a motor vehicle accident and sustained a right Le Fort III fracture and multiple displaced, comminuted fractures of the anterior wall of the frontal sinus, nasal bones, right orbital rim, right zygoma, and both orbital floors with symptomatic diplopia. Open reduction and internal fixation of the acutely displaced facial fractures were performed initially, followed 3 months later by open reduction of the nasal fracture and septal reconstruction.

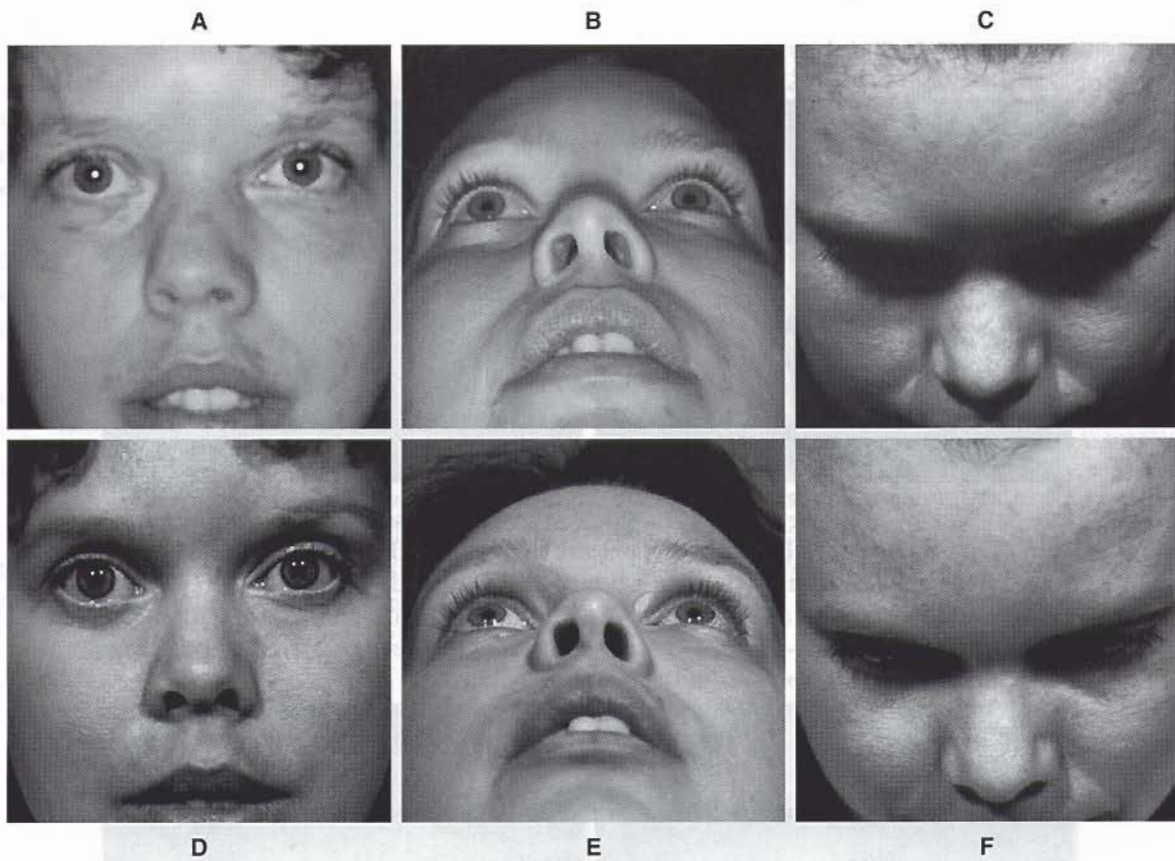
Eighteen months later, residual skeletal defects were confined to the right orbitomaxillary and glabellar regions of the face, with posterior retraction of the right ala (Fig. 20-2, A and C). The patient also had symptoms of facial dysfunction that were located over the areas of maximum bone loss. In addition to the well-delineated bone defects, the anatomic model revealed a retrodisplacement of the right premaxillary-nasal complex that could not otherwise have been discerned preoperatively in so precise and quantitative a manner (Fig. 20-2, B and D). The maxillary wax template was devised to fill the defect and also match the normal contralateral left frontal process of the maxilla and nasal bone (Fig. 20-3, A and B). A second template was made to recontour the midforehead. During the outpatient surgery the right premaxillary defect was approached by means of an intraoral route (Fig. 20-3, C) and the midforehead defect by means of a coronal approach (Fig. 20-3, D). Emphasis was placed on completely undermining and freeing the periosteum, particularly if it was entrapped within old fracture sites. Once the implants were in position, the stability provided by the accurate fit between the implant and corresponding surface of bone made supplemental fixation with sutures or screws unnecessary.

Fifteen-month-postoperative photographs (Fig. 20-4) reveal the results. After 4 years of follow-up there were no complications, the implants were not palpable and were undetectable, and the contour changes remained constant. The patient reported the return of normal facial function in the areas where the bone deficits were restored.

**FIGURE 20-2** Case 1. Two areas of residual surface contour defects 18 months after primary reconstruction. **A**, A bone defect is seen as a depression over the right infraorbital rim and nasomaxillary region (arrow). **B**, The defect in the anatomical model (arrow) directly corresponds to the clinical presentation in **A**. **C**, The flattened area over the glabella and medial forehead corresponds to the defect within the glabella illustrated by the anatomical model (**D**). In this view of the anatomical model, one can also fully appreciate the retrodisplacement of the right premaxillary-nasal complex. (From Binder W, Kaye A: Utilizing 3-D computer modeling to create custom-designed implants to reconstruct posttraumatic and congenital facial contour deformities, *Plast Reconstr Surg* 94(6):775-785, 1994.)



**FIGURE 20-3** Case 1. **A**, Frontal view with template designed on the model to reconstruct the orbitonasomaxillary defect. (The orbital nerve, avulsed in the primary injury, was not a factor in the design of the template.) **B**, The template fills the bone defect and also compensates for the right posterior nasomaxillary displacement by matching its structure to the normal contralateral side. **C**, An intraoral approach used to access the maxillary defect shows the implant being positioned. The implant fit precisely into the defect without requiring modification or fixation. **D**, A coronal approach was used to access the midforehead defect where the implant was placed into position also without requiring fixation. (From Binder W, Kaye A: Utilizing 3-D computer modeling to create custom-designed implants to reconstruct posttraumatic and congenital facial contour deformities, *Plast Reconstr Surg* 94(6):775-785, 1994.)



**FIGURE 20-4** Case 1. A to C, Preoperative views. D to F, These postoperative photographs taken 15 months after implant surgery demonstrate complete reconstruction of the right orbitomaxillary and mid-forehead defects. After a 4-year follow-up the implants have continued to maintain the reconstruction, remaining stable, impalpable, and undetectable. (From Binder W, Kaye A: Utilizing 3-D computer modeling to create custom-designed implants to reconstruct posttraumatic and congenital facial contour deformities, *Plast Reconstr Surg* 94(6):775-785, 1994.)

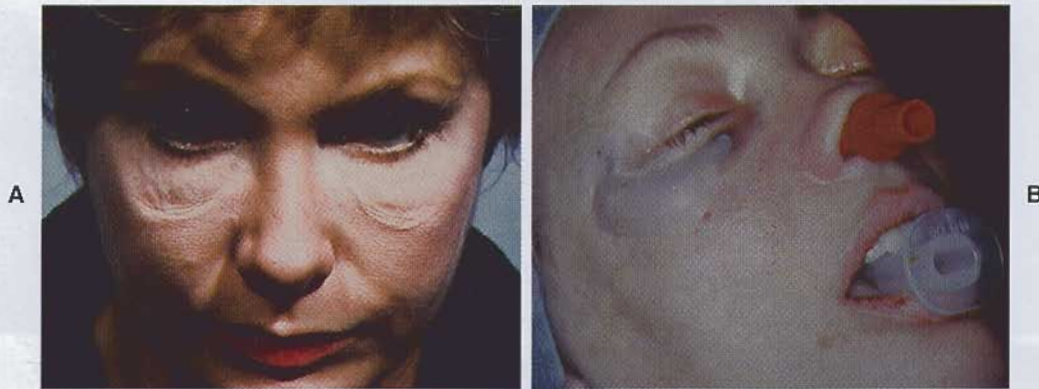## Case 2

A 45-year-old woman presented with an unusually severe periorbital soft tissue problem: two blepharoplasties and numerous chemical peels had caused severe atrophy, discoloration, and permanent wrinkling of the lower eyelid skin, dermis, and subcutaneous tissue. Other attempts to reconstruct this area, including fascial and dermal fat grafts and numerous fat injections, provided no improvement (Fig. 20-5, A).

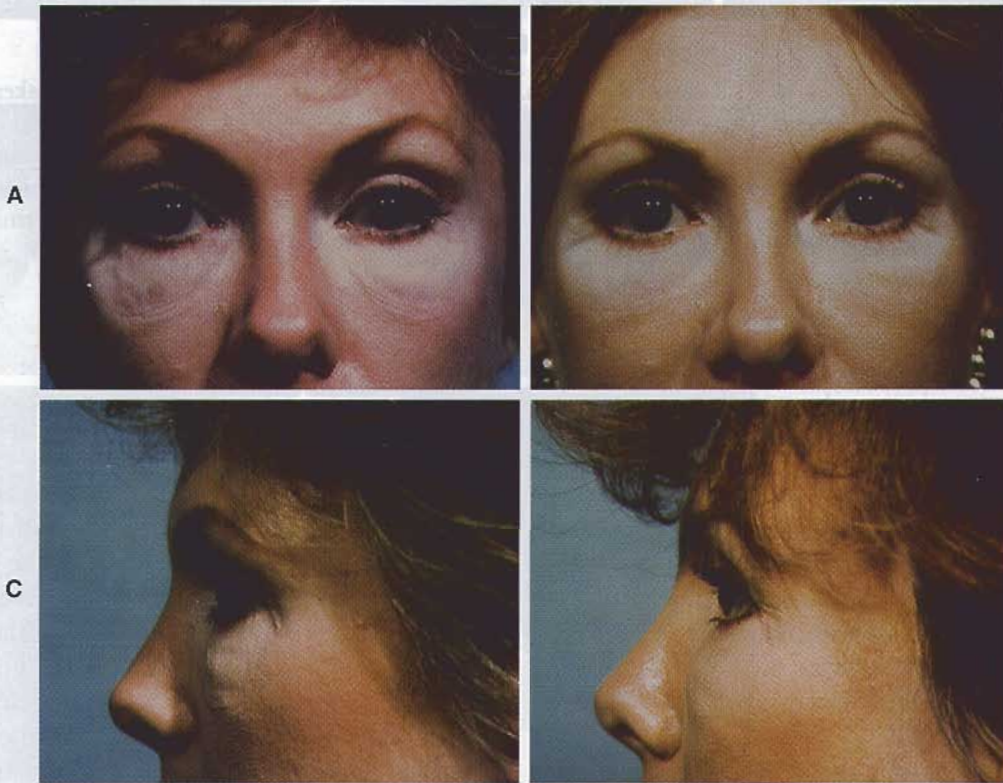Since these previous soft tissue procedures had not been effective, custom onlay implants were designed to change the configuration of the underlying periorbital skeletal structure and to make the lower eyelid and in-

fraorbital skin drape in a horizontal and lateral orientation, thus reducing the vertical extent of the deformity (Fig. 20-5, B). Because of the laxity of the lower eyelids, an intraoral approach was used to develop a pocket along the infraorbital rim, circumferentially dissecting out the infraorbital nerve. The implants' precise fit to the bony contour correctly positioned them, and they required no fixation. There were no paresthesias of the infraorbital nerve nor other postoperative complications. The patient has been followed for over 2½ years: the implants remain stable, and the results of surgery are successfully maintained (Fig. 20-6).

FIGURE 20-2 Case 1. Treatment



**FIGURE 20-5** Case 2. **A**, Because of severe atrophic skin changes, a distinct line of demarcation and obvious disfigurement had developed between the damaged eyelid skin and the normal, thicker cheek skin. **B**, Intraoperatively, the implant positioned over the defect. The shape and thickness of the implant were designed to displace the skin in an anterior and lateral direction. (From Binder W, Kaye A: 3-D computer modelling: used to create custom-designed implants for treating aesthetic and acquired facial contour deformities, *Facial Plast Surg Clin North Am* 2(3):357-371, 1994.)

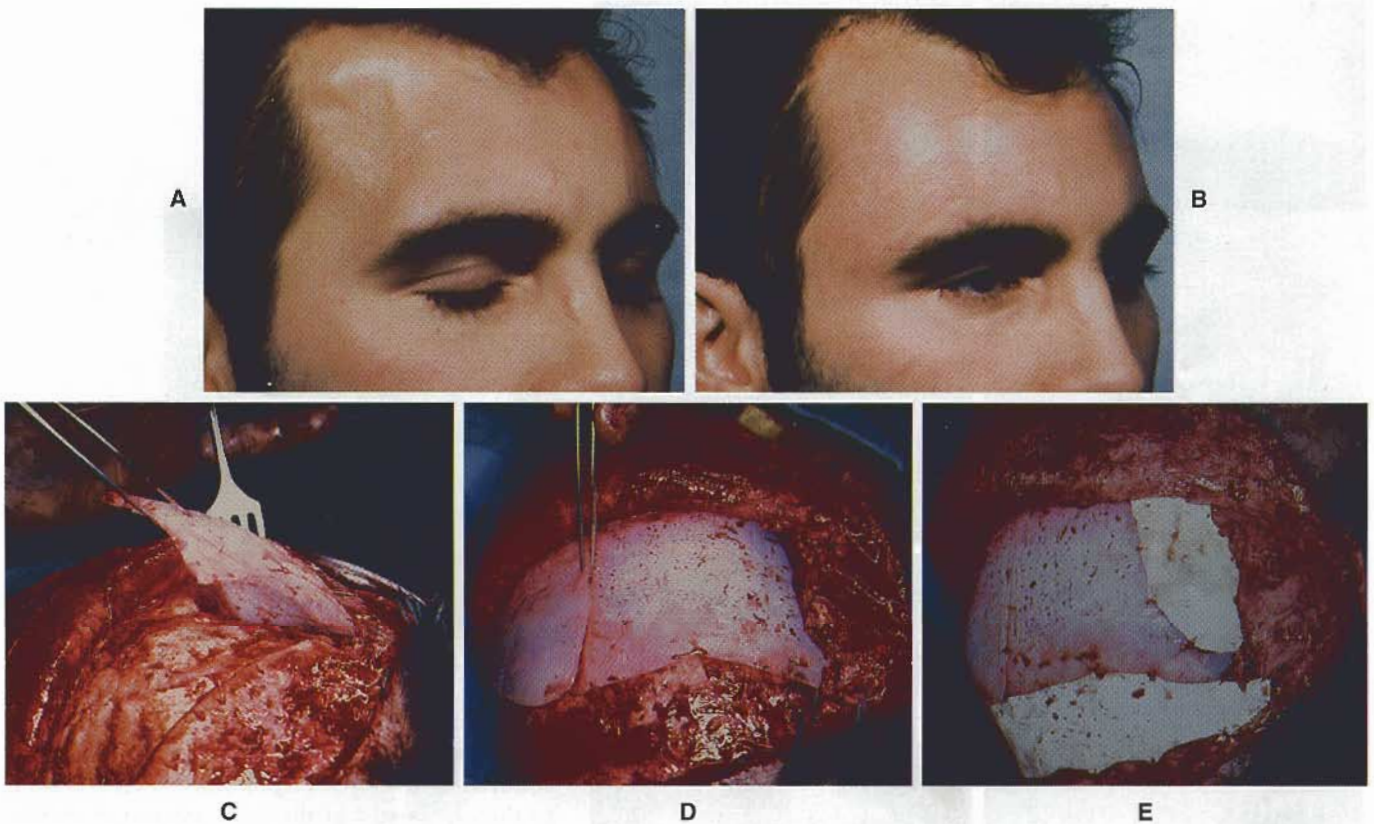


**FIGURE 20-6** Case 2. **A** and **C**, Severe periorbital integumentary disfigurement. **B** and **D**, The degree of permanent correction achieved by the implant procedure 11 months after surgery. (From Binder W, Kaye A: 3-D computer modelling: used to create custom-designed implants for treating aesthetic and acquired facial contour deformities, *Facial Plast Surg Clin North Am* 2(3):357-371, 1994.)

### Case 3

When this 28-year-old man was thrown from an automobile, he sustained massive craniofacial injury, which included a fractured cranium, fracture of the right orbit, a Le Fort III fracture of the upper third of the face, and a fractured nose and right maxilla. He also sustained herniation of the brain with loss of vision in the right eye necessitating a series of three life-saving craniotomies. Bone flaps were performed for each procedure, and subsequently a cranioplasty was also performed for reinsertion of the bone flap, which left a large residual defect over the right temporal area (Fig. 20-7, A). Intraoperatively (Fig. 20-7, C) the implant was made to fit the entire temporal and frontal depression precisely. The thicker portion of the implant was placed deep to the muscle to fit into the displaced temporal fossa. For the implant to be large enough to encompass the temporal and the frontal area it had to be made in two parts,

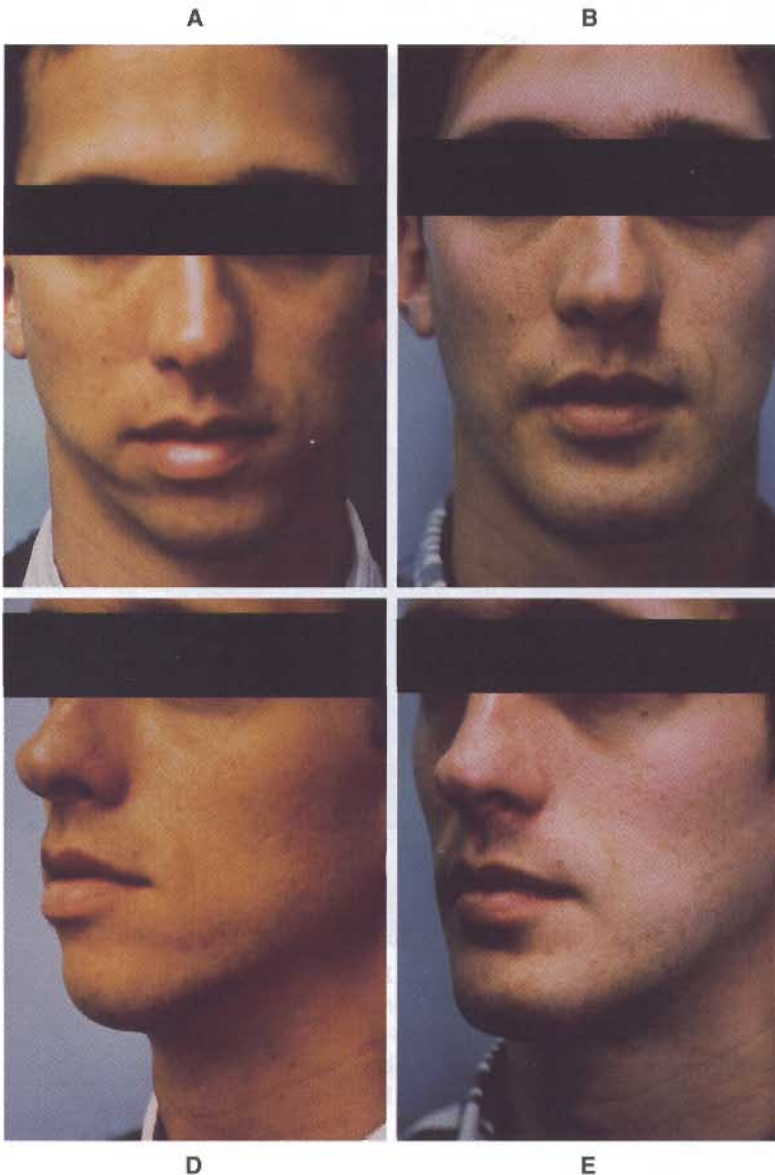
which were placed next to each other and then sutured together (Fig. 20-7, D). Since this was such a large implant as well as large area to reconstruct, additional stability was obtained by suturing the Gore-Tex 1 mm soft tissue patch to the edges of the implant and the periosteum covering normal bone and temporalis muscle (Fig. 20-7, E). This not only contributed to the implant but also helped to provide a smoother transition between the implant and surrounding structures. This procedure was performed in November 1993. The postoperative photograph (Fig. 20-7, B) was taken 2 years after surgery. The defect has been reconstructed successfully with near perfect symmetry to the external contour of the temporal area so that the implant cannot be detected visually nor the edges of the implant palpated. The patient has now been followed for 6 years with no postoperative complications.



**FIGURE 20-7** Case 3. **A**, Preoperative. **B**, 2 years after surgery. The entire right temporal area has maintained its shape and stability with normal sensation and motion for the more than 3 years that the patient has now been followed postoperatively. **C**, Intraoperatively the thicker lateral portion of the implant is placed deep to the temporalis muscle into the posteriorly displaced temporal fossa. **D**, The implant was too large to be molded as one implant. The more central portion of the implant, however, fits perfectly in place adjacent to the lateral part of the implant. **E**, Additional stabilization is furnished by a 1 mm Gore-Tex patch, which is sutured to the implant and then attached to the temporalis muscle laterally and the periosteum superiorly.

### Case 4

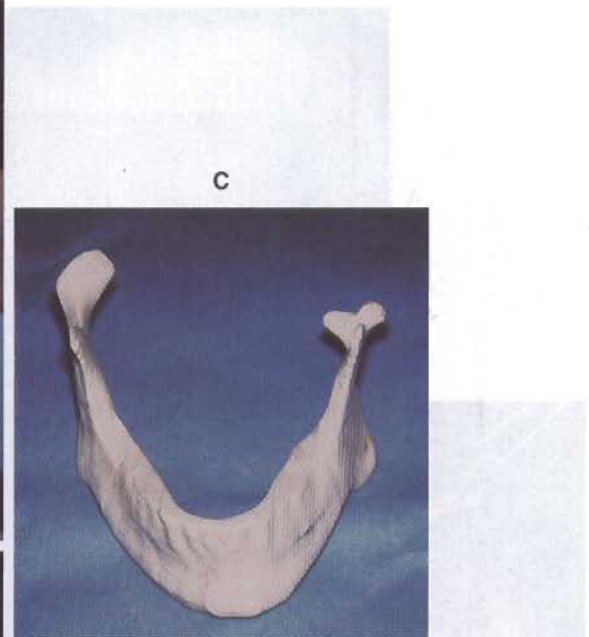
This 32-year-old patient presented with a congenital malformation of the mandible (Fig. 20-8, A and D). In addition to demonstrating anterior mandibular asymmetry the 3D model was able to demonstrate a developmental mandibular condylar deformity that also contributed to the frontal abnormality (Fig. 20-8, C). Using the model as a reference point to work from, we planned the implant by estimating the amount of posterior displacement of the mandible, which also contributed to the actual right anterior, parasymphyseal, and lateral mandibular deficiencies. Intraoperatively the implant fell into perfect alignment, and only a minor adjustment to the thickness of the implant over the right parasymphyseal area was necessary. Figure 20-8, B and E, shows the 6-month postoperative result.



### Case 5

This 42-year-old man had undergone malar augmentation a few years before evaluation. He also previously had two unsuccessful chin implant procedures, after each of which the implant was removed. The laterally positioned malar implants were malpositioned, producing an unsatisfactory cosmetic result (Fig. 20-9, A and D). Since the patient's personal circumstances necessitated performing a one-stage procedure and with the existing implants camouflaging a major degree of underlying skeletal asymmetry, it was decided that the most accurate method to obtain a successful result was to design custom implants via the 3D imaging and modeling process.

After the CT scan was taken, a second set of 3D images was made to include the existing implants within



**FIGURE 20-8** Case 4. A and D, Preoperative. B and E, 9 months after surgery. C, The model clearly demonstrates the degree of right mandibular condylar deficiency. Its significance in contributing to the asymmetry of the right anterior mandible could be fully appreciated only after examining the model and assessing all the parts contributing to the complete defect.



the radiograph. The 3D radiograph showed a portion of each malar implant was positioned above the orbital rim and encroaching on the orbit (Fig. 20-9, C).

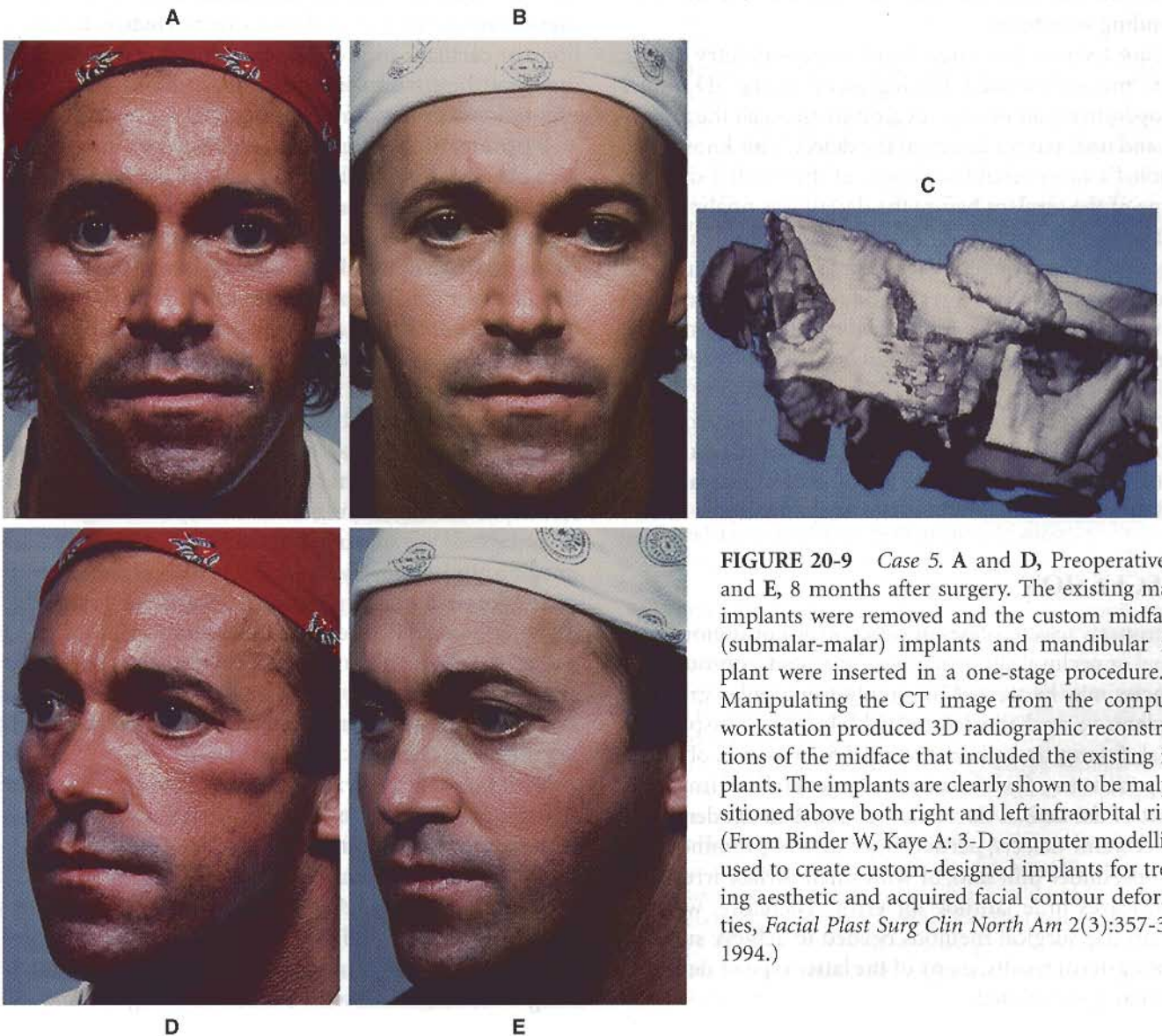
After the model was obtained, wax templates were designed according to the underlying skeletal deficiencies. Augmentation was required in both the submalar and malar areas. The measurements taken of the existing implants from the computer image were used as a guide for approximating the thickness of the custom implants over the malar region. This enabled the revisional midfacial augmentation to remove the old and insert the new custom implants in a one-stage procedure. A wrap-around chin implant was also designed to balance the face by increasing the overall dimension to the symphyseal and parasymphyseal portions of the mandible (Fig. 20-9, B and E).

## REVIEW OF CASE REPORTS

A common element in all the cases presented is that without the 3D CAD-CAM model and implant design process, satisfactory diagnosis and the degree of accuracy obtained in the reconstruction would have been more difficult.

Case 1 illustrates the advantages of this process in the treatment of complex, finite posttraumatic facial contour deformities. The custom onlay prosthetics reconstructed the bone defects over the infraorbital and glabellar areas without incurring postoperative irregularities of grafts or standard implants. Being able to design the template before surgery to overlap margins around the bone defects or to feather its edges renders the implant virtually undetectable.

In Case 2 the patient presented with an unusual, but



**FIGURE 20-9** Case 5. A and D, Preoperative. B and E, 8 months after surgery. The existing malar implants were removed and the custom midfacial (submalar-malar) implants and mandibular implant were inserted in a one-stage procedure. C, Manipulating the CT image from the computer workstation produced 3D radiographic reconstructions of the midface that included the existing implants. The implants are clearly shown to be malpositioned above both right and left infraorbital rims. (From Binder W, Kaye A: 3-D computer modelling: used to create custom-designed implants for treating aesthetic and acquired facial contour deformities, *Facial Plast Surg Clin North Am* 2(3):357-371, 1994.)

distinct soft tissue deformity. Implants were used to change the draping and orientation of the skin from a vertical to a horizontal position by augmenting the peri-orbital bone structure. The augmented contour also expanded the contracted, atrophic skin outward to a more superior and anterior location, additionally smoothing out some of the wrinkling and providing the appearance of an increase in soft tissue bulk in this area.

Case 3 represents a postoperative cranial defect that presented significant reconstructive challenges. One challenge was posed by the possible movement of the relatively large, bulky implant by the masseter muscle. This represents one of the first cases in which a Gore-Tex 1 mm soft tissue patch was used. Suturing the Gore-Tex around the edges of the implant and attaching it to the surrounding structures gave the implant greater latitude for movement while maintaining it in a reliably stable position. It also contributed to a smoother, undetectable transition between the silicone implant and the surrounding structures.

Case 4 shows how large degrees of asymmetry can be more precisely treated. Having access to the 3D model preoperatively allows the surgeon to assess all the apparent and unapparent causes of the defect. This knowledge enabled a more reliable estimate of the needed size and shape of the implant before the design was finalized.

The patient described in Case 5 had a problem often encountered in aesthetic facial contouring: implants already in place from previous surgery presented unknown variables and camouflaged existing asymmetries. Current software enables manipulation of the digital information provided by the CT scan so that the existing implants can be added or subtracted from the image to obtain a true 3D rendering of only the skeletal structure or the augmented structure for more accurate analysis and ultimate correction of skeletal asymmetry.<sup>10</sup>

## DISCUSSION

In properly selected cases in which major or minor functional or occlusal abnormalities are absent, contour deficiencies may be treated by simply using onlay grafts or implants to mask the deformity.<sup>1,27</sup> In large, conspicuous facial deformities, where the need for repair is obvious, the patient usually is satisfied with generalized improvement of the defect. Correction of small-to-moderate facial contour defects, particularly those in prominent locations, under thin skin, or with small surface irregularities, leaves little latitude for error. Therefore, without the precise surgical methods needed to achieve successful long-term results, many of the latter type of deformities may go untreated.

In moderate-to-severe cases of maxillofacial trauma, malunion and displacement often result in postoperative asymmetry and resultant problems in facial contour.<sup>16</sup> Even with adequate and timely management, comminuted bone fragments or incomplete reduction may cause late resorption or partial collapse that may not become apparent until months later.<sup>4,22</sup> Inconsistencies of overlying soft tissue change can also diminish the outcome of an otherwise well-executed segmental bone-repositioning procedure.

Generally it is easier to predict soft-tissue displacement following direct augmentation using grafts or implants than with osteotomies and segmental bony repositioning. Although it is theoretically preferable to use the patient's own tissues when augmentation is desired, the disadvantages of doing so are many. Currently there is no soft tissue material guaranteed to last or retain its volume or stability as a replacement for original tissue or normal structure. Harvesting autogenous bone always carries with it the risk of donor site morbidity. To shape bone or cartilage to precisely fit a defect is difficult and increases the surgical time, and bone and cartilage have unpredictable rates of resorption.<sup>6,13,14</sup>

Biocompatible alloplastic implants are more predictable and durable than autogenous grafts. Trying to carve blocks of alloplastic material to fit irregular skeletal defects, however, is difficult and time consuming and yields less than optimal results. In cases that are not routine, more conventional "off-the-shelf" implants or prefabricated implants made from mouldages have similar problems of adaptation and difficulty in conforming to the underlying skeletal morphology, which may produce implant instability and palpability.<sup>4,11,15</sup>

Long-term success with large implants or placement over irregular bone surfaces depends upon implant conformity to the underlying features. The most significant advantage of the custom implant produced by the 3D imaging and modeling process is the accuracy with which the posterior implant surface conforms to the underlying bone. Three-dimensional computer modeling allows the fabrication of versatile implants that wrap around corners and fit into niches to effectively address minor surface discrepancies or irregularities surrounding the defect.

To accurately analyze and predict external contour changes produced by the insertion of an implant or graft between bone and soft tissue is a formidable challenge for the computer because of the infinite variations in overlying integument. This assessment is still best done by visual estimate and direct measurement. To resolve some of these limitations, computer imaging and modeling were combined with surface molding techniques.

The anatomical model displays the deformity, and visual and physical analyses by the surgeon ascertain the need for any additional design modifications in the template. Molding the wax template on the actual anatomical model factors in minor discrepancies that cannot be appreciated by the computer image alone. This additional step ensures a smooth transition from the borders of the implant to the surrounding irregularities of the defect and further reduces the propensity for implant movement. This process also allows for appropriate changes to be made in implant volume and projection either to compensate for soft tissue loss or to obtain a desired amount of augmentation.

Although different biomaterials can be used for augmentation, only a few work with the 3D imaging-CAD-CAM process for fabrication of custom prosthetic devices. The material must be relatively inert, noncarcinogenic, flexible, and easily carved or modified if further refinements are necessary at the time of surgery. It is preferred that the implant be nonporous for greater resistance to infection.<sup>22</sup>

Coralline-derived porous hydroxyapatite (Interpore-200) is brittle, cannot be adequately milled, and has not been reliable when used as an onlay graft material in block form.<sup>17,20</sup> Rigid or inflexible implants such as methylmethacrylate or Medpor are not compressible or flexible enough for large implants to be inserted through small openings and to adapt to changes over larger surface areas. Polytetrafluoroethylene (PTFE, Proplast HA) is not suitable for use in the 3D process and is no longer commercially available in the United States.<sup>10</sup> Silicone elastomer is the only biomaterial that was able to fulfill most of the requirements of the ideal implant material while also satisfying the demands of the custom molding process. The 3D imaging and modeling system can produce a custom implant in the more stable, commercially processed, heat-vulcanized (HV) silicone elastomer in full compliance with all U.S. Food and Drug Administration (FDA) and strict Good Manufacturing Process (GMP) standards and requirements.\* The use of the traditional moulage methods of on-site custom implant fabrication is no longer possible because of the implication of impurities in noncommercial, on-site self-fabrication, of room temperature-vulcanized (RTV) silicone implants in haptogenic effects.<sup>5</sup>

Although variables in soft tissue distortion may preclude reliance on any single technique, 3D imaging and modeling is a reliable first step in this evolutionary process to achieve more accurate results in complex cas-

es of contour restoration. The integration of computerized imaging, laser scanning, and stereolithography along with other modalities for use in facial contouring will undoubtedly enhance our ability to achieve even better results in the future.

## CONCLUSION

This 3D, state-of-the-art scanning, imaging, and modeling system increases versatility and sets new standards in design and use of onlay implants for treating many difficult and challenging problems in aesthetic, traumatic, and congenital facial contour deformities. It provides a complete reconstructive modality with reduced surgery time that can be performed in an outpatient setting.

## REFERENCES

1. Belinfante L, Mitchell D: Use of alloplastic material in the canine fossa-zygomatic area to improve facial esthetics, *J Oral Surg* 35:121, 1977.
2. Binder WJ: Submalar augmentation: a procedure to enhance rhytidectomy, *Ann Plast Surg* 24:200, 1990.
3. Binder WJ: A comprehensive approach for aesthetic contouring of the midface in rhytidectomy, *Facial Plast Surg Clin North Am* 1:231, 1993.
4. Block MS, Zide MF, Kent JN: Proplast augmentation for post-traumatic zygomatic deficiency, *Oral Surg Oral Med Oral Pathol* 57:123, 1984.
5. Brantley SK, Davidson SF, St. Arnold PA, Johnson MB, Talbot PJ, Grogan JB, Cuchens MA, Hsu HS, Das SK: Assessment of the lymphocyte response to silicone, *Plast Reconstr Surg* 86:1131, 1990.
6. Dado DV, Izquierdo R: Absorption of onlay bone grafts in immature rabbits: membranous versus enchondral bone and bone struts versus paste, *Ann Plast Surg* 23:39, 1989.
7. Flowers RS: Tear trough implants for correction of tear trough deformity, *Clin Plast Surg* 18:689, 1991.
8. Freihofer HP: Soft-tissue contours after osteotomies: predictability and imponderabilities. In Ousterhout D, editor: *Aesthetic contouring of the craniofacial skeleton*, Boston, 1991, Little Brown, p 117.
9. Hemmey DC, David DJ, Herman GT: Three-dimensional reconstruction of craniofacial deformity using computed tomography, *Neurosurg* 13:534, 1983.
10. Kaplan E: 3-D CT images for facial implant design and manufacture. Facial aesthetic surgery: art, anatomy, anthropometrics, and imaging, *Clin Plast Surg* 14:663, 1987.
11. Laub DR, Spohn W, Lash H, Weber J, Chase RA: Accurate reconstruction of traumatic bony contour defects of the periorbital area with prefabricated silastic, *J Trauma* 10:472, 1970.
12. Luhr HG: The significance of condylar position using rigid fixation in orthognathic surgery, *Clin Plast Surg* 16:147, 1989.
13. Ousterhout DK: Clinical experience in cranial and facial reconstruction with demineralized bone, *Ann Plast Surg* 15:367, 1985.
14. Powell NB, Riley RW: Facial contouring with outer-table calvarial bone: a 4-year experience, *Arch Otolaryngol Head Neck Surg* 115:1454, 1989.

\*Custom implants are FDA-approved and commercially available as 3D-Accusan, Implantech, Ventura, California.

15. Raval P, Schaaf NG: Custom fabricated silicone rubber implants for tissue augmentation: a review, *J Prosthet Dent* 45:432, 1981.
16. Reynolds JR: Late complications versus method of treatment in a large series of mid-facial fractures, *Plast Reconstr Surg* 61:871, 1978.
17. Rosen H: Porous, block hydroxyapatite as an interpositional bone graft substitute in orthognathic surgery, *Plast Reconstr Surg* 83:985, 1989.
18. Rosen HM: Maxillary advancement for mandibular prognathism: indications and rationale, *Plast Reconstr Surg* 87:823, 1991.
19. Salyer KE, Gudmundsen A: Facial balance and harmony through the use of split bone techniques. In Ousterhout D, editor: *Aesthetic contouring of the craniofacial skeleton*, Boston, 1991, Little Brown, p 333.
20. Salyer KE, Hall CD: Porous hydroxyapatite as an onlay bone-graft substitute for maxillofacial surgery, *Plast Reconstr Surg* 84: 236, 1989.
21. Salyer KE, Taylor DP, Billmire DE: Three-dimensional CAT scan reconstruction: pediatric patients, *Clin Plast Surg* 13:463, 1986.
22. Schultz RC: Reconstruction of facial deformities with alloplastic material, *Ann Plast Surg* 7:434, 1981.
23. Terino EO: Alloplastic facial contouring by zonal principles of skeletal anatomy, *Clin Plast Surg* 19:487, 1992.
24. Vannier MW, Marsh JL, Warren JO: Three dimensional computer graphics for craniofacial surgical planning and evaluation, *Comp Graph* 17:263, 1983.
25. Vannier MW, Pilgram TK, Bhatia G, Brunson B, Nemecek JR, Young VL: Quantitative three-dimensional assessment of face-lift with an optical facial surface scanner, *Ann Plast Surg* 30:204, 1993.
26. Watanabe K, Mayagi H, Tsurukiri K: Augmentation of the temporal area by insertion of silicone plate under the temporal fascia, *Ann Plast Surg* 13:309, 1984.
27. Whitaker LA, Pertschuk M: Facial skeletal contouring for aesthetic purposes, *Plast Reconstr Surg* 69:245, 1982.
28. White DN: CT scans, multidimensional reformatting, and CAD/CAM-produced modes in the diagnosis and treatment of craniofacial deformity. In Ousterhout D, editor: *Aesthetic contouring of the craniofacial skeleton*, Boston, 1991, Little Brown, pp 95-108.